



THE COLLEGE OF
OPTOMETRISTS

Stage Two

Overarching case scenario 16

AGE AND GENDER 67 years, Male

ETHNIC BACKGROUND Caucasian

OCCUPATION AND HOBBIES: Retired book-keeper. Hobbies: Watching sport on TV

PRESENTING SYMPTOMS AND HISTORY: Has not been well recently. In-patient in hospital for two months following stroke: now been out of hospital for two months. In wheelchair at present. Right side of body affected. Since coming out of hospital finds it very difficult to read. Spectacles worn all the time, but thinks they need improving. LEE 1 year ago, advised of mild age changes in the eye. Father had glaucoma.

GENERAL HEALTH AND MEDICATION Half an aspirin each morning at present.

PRESENT Rx, CENTRATION AND ACUITIES with current varifocals

R +3.50 /-2.25 x 90 6/9 Near Add +2.50 N6

L +3 .50/-2.50 x 85 6/9+2 Near Add +2.50 N6

mono cd RE 33.5 LE 32.5

PD/NCO 66/61 mm

VISION R 6/60 N24 L 6/60 N24

PINHOLE VISION R 6/9+1 L 6/7 .5

REFRACTION

R +3.75/-2.00 x 95 Near Add +2.50 DS

L +3 .25/-2.00 x 85 Near Add +2.50 DS

VA

Distance R 6/9+1 L 6/7 .5

Near R N5 slow L N5 slow (40cm working distance: needs to rest book on arm of chair)

ACCOMMODATION R 0.5 L 0.5

BINOCULAR STATUS

Cover test: D NMD N 4 prism XOP

MOTILITY Full with no discomfort

CONVERGENCE 20cm

PUPIL REACTIONS D,N,C full but slow R & L. No RAPD

FUNDUS EXAMINATION see attached

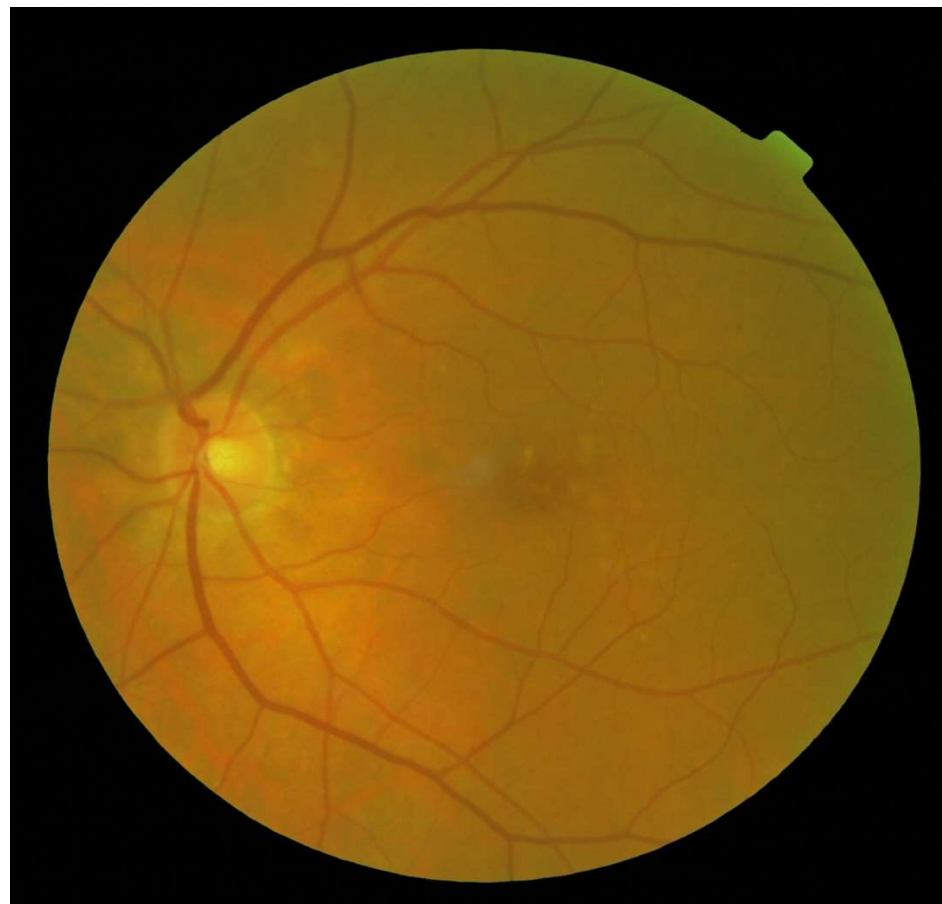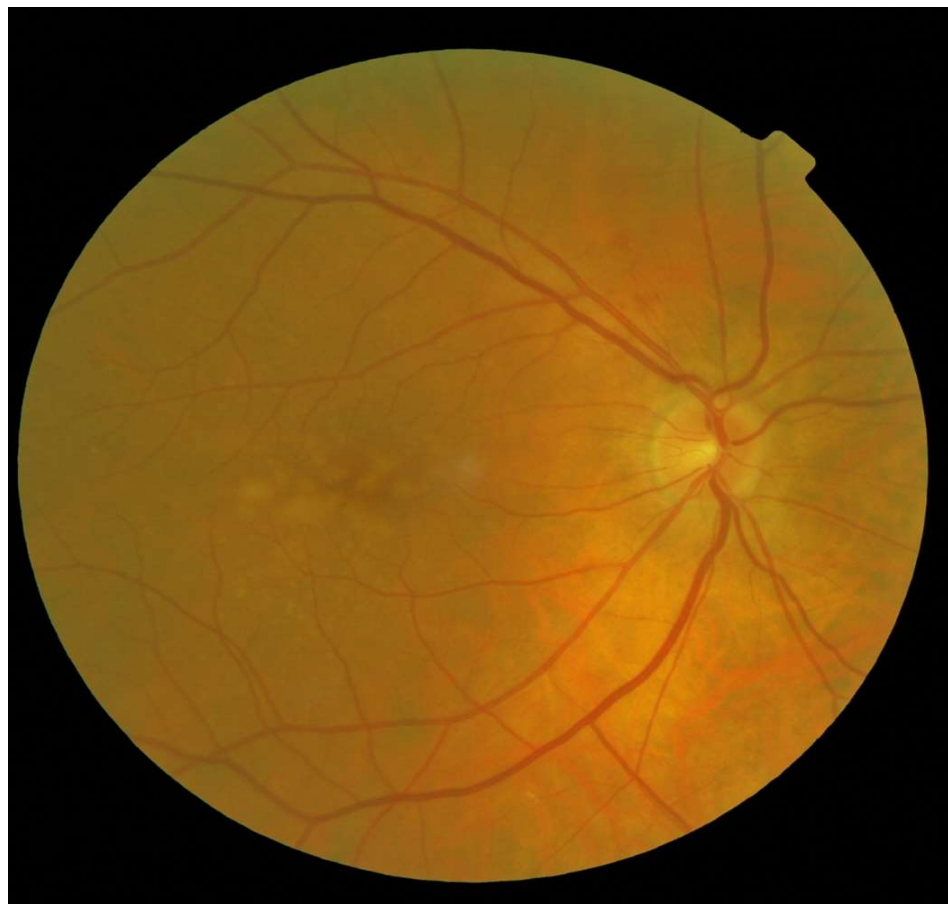FIELDS see attached

IOP R 10mmHg L 10mmHg @ 3.30pm Perkins

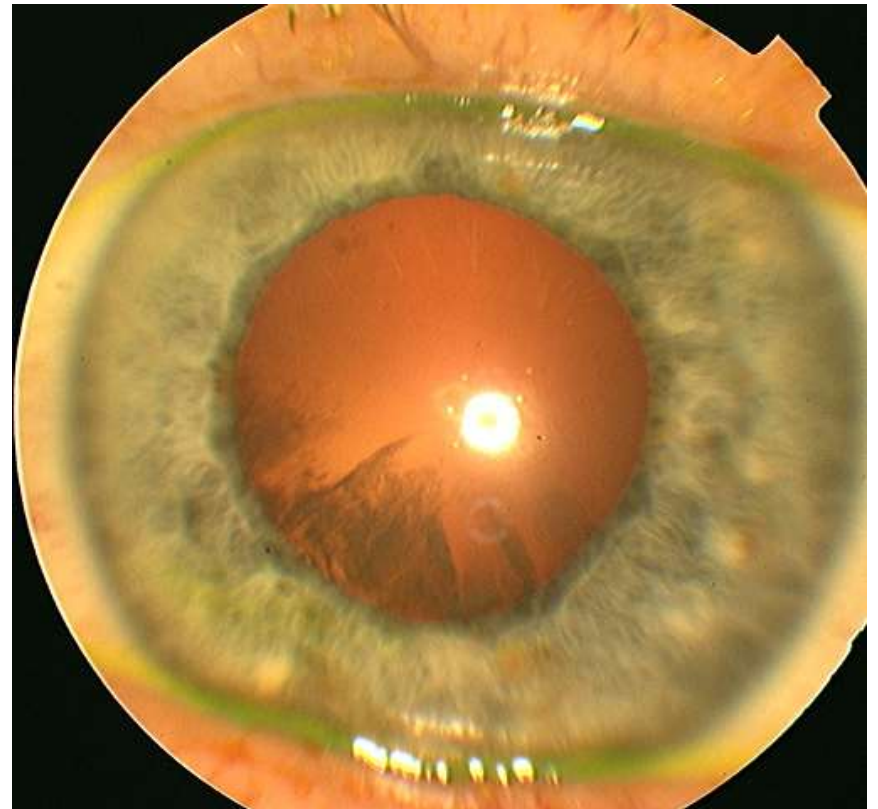
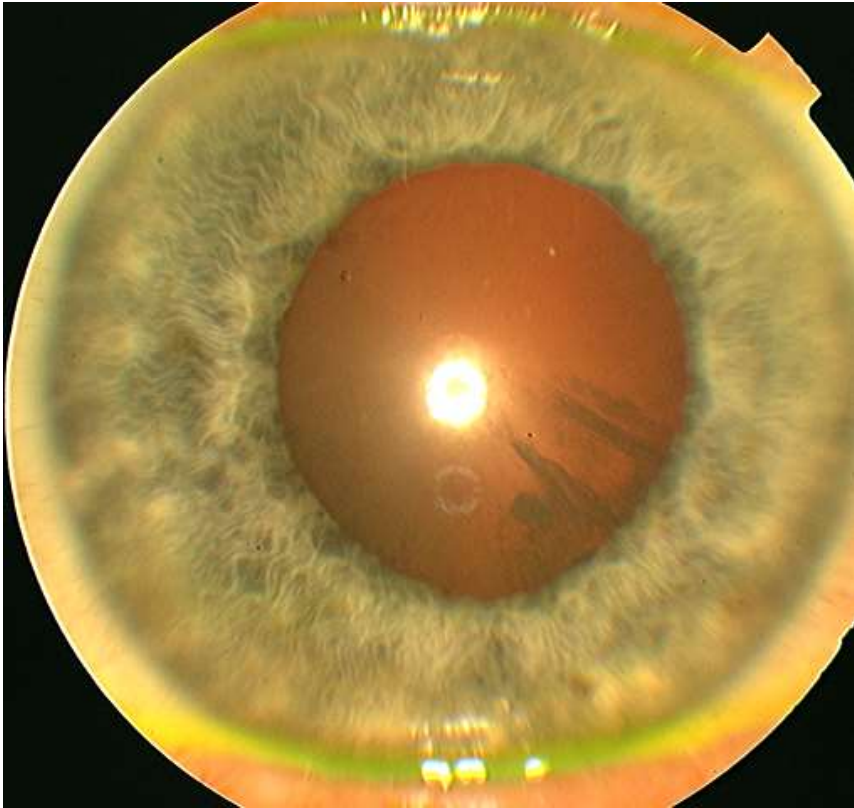EXTERNAL EYE EXAMINATION see attached

COLOUR VISION Not undertaken

Fundus Image



External Eyes



Field RE & LE

